

## COMMENTARY



# Advanced fibroid study: paying homage to John Sampson

John L Yovich<sup>1,2,3,\*</sup>, Philip K Rowlands<sup>1</sup>, Sunthra Lingam<sup>3</sup>, Mark Sillender<sup>1</sup>, Shanthi Srinivasan<sup>1</sup>

## ABSTRACT

A recent article supports our longstanding view that all intramural fibroids can cause disturbance of uterine function. This may be reflected in the symptom of menorrhagia or fertility-related issues, as well as pregnancy losses at all gestational stages. However, it was disappointing that there was no reference to either the mechanism by which fibroids disturb uterine function nor to the gynaecologist who described this more than 100 years ago, namely John Sampson. In fact, Sampson's findings about the unique venous drainage mechanism from the endometrium explains how menstrual loss is contained in normal physiology, but which can be excessive when the protective 'anaemic' zone is disturbed. Two more recent and pertinent observations include the hysteroscopic findings of Osamu Sugimoto, who showed in the 1970s that the endometrium overlying submucous fibroids is actually atrophic, hence the oft-cited reason of hyperplastic or excessive endometrium cannot be the cause of the associated menorrhagia. Furthermore, recent imaging techniques describe an additional 'junctional zone' adjacent to the endometrium in cases of fibroids and adenomyosis. We believe this all adds up to disturbed venous drainage as described by Sampson and needs to immediately enter the educational training of medical students, doctors and gynaecologists worldwide.

## INTRODUCTION

As gynaecologists we have undertaken myomectomy procedures within established specialty practice ranging since 1976 (JLY), progressing to laparoscopic myomectomy procedures since 1991. We have maintained a focused interest in publications concerning leiomyomata (fibroids) and the ultrasonically similar but pathogenically very different condition of adenomyosis (Yovich *et al.*, 2019). In particular the influence of these uterine masses on menstruation and fertility has created a lifelong conundrum based on publications from prominent sources that do not actually project the same scientific viewpoint. For instance, FIGO classification appears to regard fibroids

as inert marbles, which only cause problems when they impact physically on the endometrial cavity, a view constantly projected by the Practice Committee of the American Society for Reproductive Medicine. This teaching has placed our group of advanced laparoscopic surgeons in a rather embarrassing position when advising young consultants who have recently completed their RANZCOG training programme. We are faced with having to explain that their teaching has been deficient, based upon poor and frankly incorrect premises.

## NEW LIGHT

However, a recent article published in the esteemed Journal of Minimally Invasive Gynecology supports our

longstanding view that all intramural fibroids can cause disturbance of uterine function (Behbehani *et al.*, 2018). This may be reflected in the symptom of menorrhagia or in the causation of pregnancy losses at all gestational stages as well as the causation of infertility. This article derives from the team at McGill University in Montreal headed by Professor Michael Dahan. They conclude that "relatively small (>1.5 cm) non-cavity-distorting intramural myomas negatively affect clinical pregnancy rate and live birth rate in IVF cycles, even in the presence of only one myoma". These data support an earlier publication indicating intramural fibroids associate with suboptimal outcomes from fertility treatments including IVF and related procedures (Sunkara *et al.*, 2010).

## KEYWORDS

Anaemic zone  
Disturbed venous drainage  
Junctional zone  
Menorrhagia  
Menstruation  
Uterine vasculature

<sup>1</sup> PIVET Medical Centre, Perth, Western Australia 6007, Australia

<sup>2</sup> Curtin University, Perth, Western Australia 6845, Australia

<sup>3</sup> Cairns Fertility Centre, Cairns, Queensland 4870, Australia

© 2019 Reproductive Healthcare Ltd. Published by Elsevier Ltd. All rights reserved.

\*Corresponding author. E-mail address: jlyovich@pivet.com.au (J. L. Yovich). <https://doi.org/10.1016/j.rbmo.2019.04.013>  
1472-6483/© 2019 Reproductive Healthcare Ltd. Published by Elsevier Ltd. All rights reserved.

Declaration: The authors report no financial or commercial conflicts of interest.

These data support our longstanding view of offering myomectomy along with pelvic tidy-up in women with infertility, especially those who have experienced failure(s) in IVF programmes (Yovich *et al.*, 1989). We recommend that women of advanced ages ( $\geq 38$  years) should have myomectomies prior to any IVF, given the investment involved and the restricted prognosis already prevailing.

## PERTINENT OBSERVATIONS OVER A CENTURY

There are three important observations that should now be clarified in order to complete the picture concerning the impact of uterine fibroids, as follows.

### Uterine vascular configuration

In a series of three important articles, John Sampson, working in Albany, New York, undertook unique experiments with 150 hysterectomy specimens. Over a 2-year period Sampson described his technique as follows:

The uterus removed at operation or autopsy was placed in a basin of warm water and the uterine cavity was filled with melted gelatine (15%) containing in suspension bismuth subcarbonate or barium sulphate. This was introduced through the cervical canal by means of a glass syringe. After filling the cavity with the mass, the syringe was withdrawn, the cervix clamped in order to prevent the escape of the mass and the specimen placed in cold water until the gelatine had solidified. Stereoscopic X-rays of the specimen enabled one to obtain a clear picture of the form of the uterine cavity under various conditions.

Interestingly Sampson noted that the endometrium created a barrier to vascular entry of the bismuth–gelatine solution, but venous entry occurred at menses and in the presence of fibroids. He then also injected uterine arteries and uterine veins, along with venous sinuses and lakes associated with fibroids. This enabled him to generate a series of pictures regarding the uterine vascularity under normal as well as abnormal situations due to fibroids or adenomyosis. The pictures are classical and were discovered while our lead author was undertaking library-based research for an invited article on menorrhagia (Yovich, 1979). We include just one of Sampson's figures (FIGURE 1A; venous system) derived from his presentation at the Forty-

third Annual Meeting of the American Gynecological Society, Philadelphia, May 16–18, 1918, where he presented 15 unique pictures from a larger series totalling 54 (Sampson, 1918). Sampson's articles explain that even peripheral intramural fibroids can impact negatively on the endometrium by disrupting the 'anaemic' or protective venous zone which normally prevents backflow or back-pressure to the endometrium (Sampson, 1912, 1913). From the three cited articles, we have developed a stylized diagram to depict and, hopefully, better explain Sampson's findings (FIGURE 1B).

### Hysteroscopic view of submucous fibroids

While preparing the earlier article on menorrhagia, JLY was also impressed by the writings of Dr Osamu Sugimoto from Osaka, Japan. Comments and a figure were derived from his book covering diagnostic and therapeutic hysteroscopy (Sugimoto, 1978a, 1978b) and included in the article on menorrhagia (Yovich, 1979). Citing from the article:

Certain pelvic diseases have traditionally been regarded as causing menorrhagia. Commonly, benign tumours such as fibroids are considered to cause heavier bleeding because of a larger endometrial surface area. However, hysteroscopists have been impressed with the relative thinness of endometrium overlying submucous fibroids. There is an unpredictable association of menorrhagia with fibroids although it does appear the more centrally located the tumour in the uterus, the more likely there is heavy menses. The true mechanism is probably associated with derangement of the venous drainage mechanism known to occur within the fibroid uterus. This may also be the basis of menorrhagia associated with adenomyosis and other bulky uterine states.

### Advanced imaging modalities and the 'junctional zone'

In recent times an impressive line-up of imaging experts known as the Morphological Uterus Sonographic Assessment (MUSA) group presented a consensus opinion of terms, definitions and measurements to describe sonographic features of the myometrium and uterine masses (Van den Bosch *et al.*, 2015). In particular the MUSA group was determined to clarify the features of adenomyosis and differentiate this condition from fibroids. They

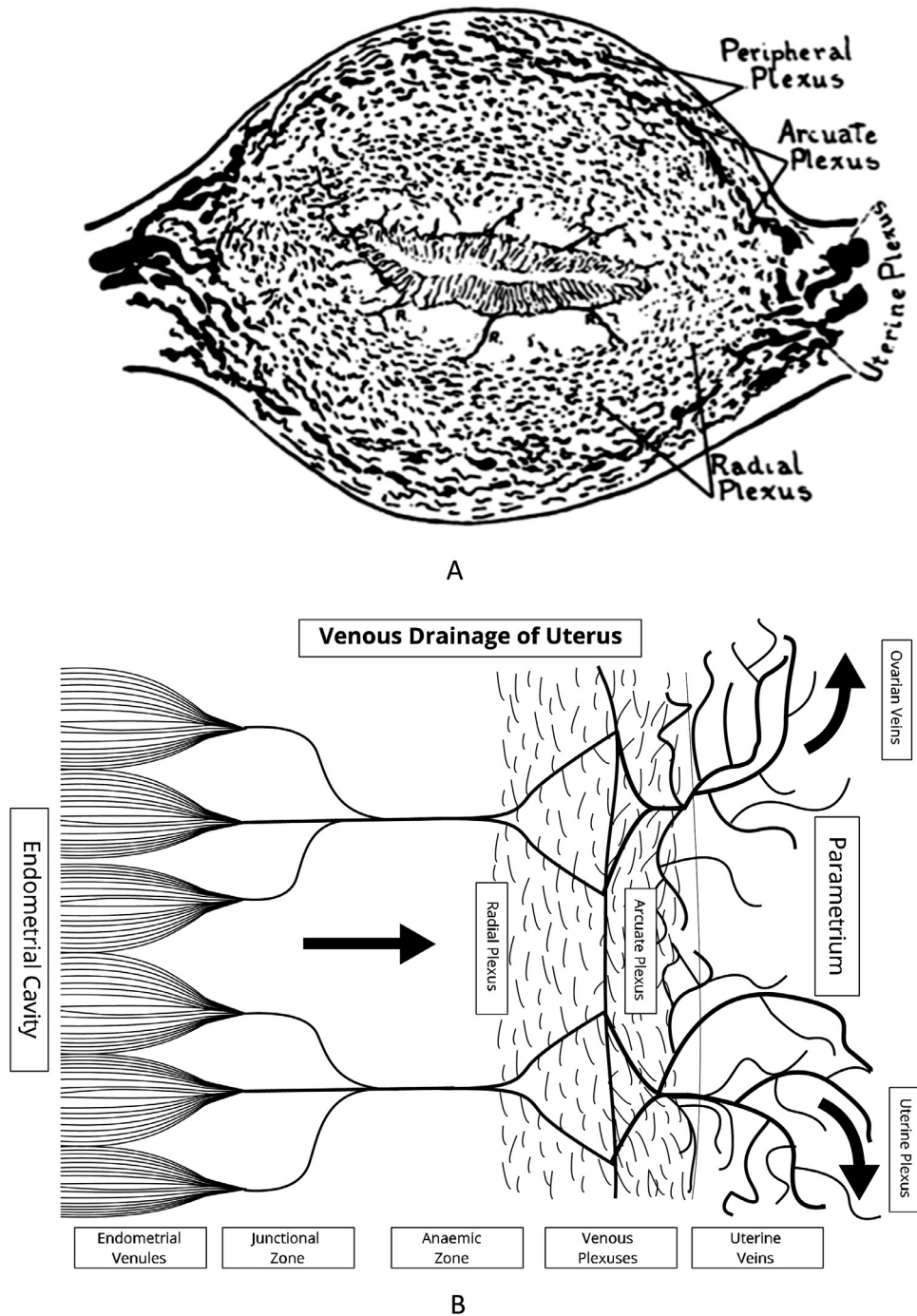
combined their findings with the more recently introduced magnetic resonance imaging (MRI) which had denoted an area adjacent to the endometrium as a 'junctional zone'. This area was noted sometimes by early ultrasound scanning of the endometrium as a surrounding hypo-echoic 'halo' of no specific relevance, but MRI studies show that it can be a pathognomonic marker for adenomyosis if the zone has a thickness exceeding 12 mm. Although the nature of the junctional zone is not fully clarified, we have included it as a feature in our stylized diagram (FIGURE 1B).

## CONCLUSION

Whilst we have welcomed the recent article in JMIG from the Canadian group of Professor Dahan (Behbehani *et al.*, 2018), there is no reference in their report to those early pioneers. We do believe that fibroids are not simply inert marbles 'lying about' in various locations of the uterus. They have significant detrimental effects on menstruation and fertility. Regardless of their siting within the uterus, they reduce the chance of successful implantation of embryos (clinical pregnancy) by 50% and increase the risk of pregnancy losses. Within IVF programmes the chance of successful live birth can therefore be reduced to around 25% of that expected in an age-matched group of women. Surely the subject of myomata is deserving of deeper studies and research, beginning with a literature review starting with the publications of John Sampson more than a century ago. At the very least, this knowledge needs to immediately enter the training education of medical students, doctors and specialists worldwide.

## ACKNOWLEDGEMENTS

The advanced laparoscopy team working in the two disparate Australian fertility centres under the direction of senior gynaecologist JLY also includes Elizabeth Jackson and Suvi Hyttinen at Cairns Fertility Centre and Dilum Madigasekara, Shipra Gaur and Kasina Venkata at PIVET Medical Centre. Special thanks to Greyling Mark Peoples, publisher of women's health journals with Elsevier and his colleague Andrea Musolf, editorial assistant with the Journal of the American College of Surgeons, who provided copies of those early articles by John Sampson. Special thanks to personal assistant Heather Lowe who applied artistic skills to FIGURE 1B.



**FIGURE 1** (A) “The venous system of the uterus as seen in cross section. The venous blood is conveyed by the arcuate plexus of veins (corresponding to the arcuate arteries) from the uterus into the uterine plexus, situated between the layers of the broad ligament. The arcuate plexus receives blood from both the peripheral and radial zones, there being a rich plexus of veins in each. The venous blood from the endometrial plexus is collected by venous sinuses at the base of the endometrium which empty into the plexus of the radial zone through ‘receiving’ sinuses (R). This area is relatively ‘anaemic’ and probably acts as a protective ‘controlling or constricting zone’ to ensure blood flows along the direction of least resistance toward the periphery into the arcuate plexus then the uterine plexus.” Source: *Sampson, 1918*. (B) Stylized diagram depicting the venous system of the uterus in part cross-section. It incorporates Sampson's findings of the ‘anaemic’ zone where endometrial blood is ‘received’ through only a few narrow veins. This region acts as a valve-like, protective layer which ensures that during uterine contractions venous blood preferentially travels towards the less resistant radial and peripheral plexus regions, which act somewhat like a sponge. However, the flow mechanism can be disrupted by intramural pathologies such as fibroids and adenomyosis which can cause congestion, oedema and menorrhagia by back-pressure on the endometrium. The junctional zone reflects the more recently described ultrasonic and MRI findings, but probably represents peri-endometrial oedema reflective of disruption to the normal venous outflow.

## REFERENCES

- Behbehani, S., Polesello, S., Hasson, J., Silver, J.M., Son, W.-Y., Dahan, M. **The effect of intramural myomas without an intracavity component on *in vitro* fertilization outcomes in single fresh blastocyst transfer cycles.** *JMIG* 2018; 25: 1241–1248
- Sampson, J.A. **The blood supply of uterine myomata.** *Surg. Gynecol. Obstet.* 1912; 14: 215–234
- Sampson, J.A. **The influence of myomata on the blood supply of the uterus, with special reference to abnormal uterine bleeding.** *Surg. Gynecol. Obstet.* 1913; 16: 144–180
- Sampson, J.A. **The escape of foreign material from the uterine cavity into the uterine veins.** *Am. J. Obstet. (and Diseases of Women and Children)* 1918; 78: 161–175
- Sugimoto, O. **Diagnostic and therapeutic hysteroscopy for traumatic intrauterine adhesions.** *Am. J. Obstet. Gynecol.* 1978a; 131: 539–547
- Sugimoto, O. **Diagnostic and therapeutic hysteroscopy.** *Igaku-Shoin.* 1978b; 230
- Sunkara, S.K., Khairy, M., El-Toukhy, T., Khalaf, Y., Coomarasamy, A. **The effect of intramural fibroids without uterine cavity involvement on the outcome of IVF treatment: a systematic review and meta-analysis.** *Hum. Reprod.* 2010; 25: 418–429
- Van den Bosch, T., Dueholm, M., Leone, F.P.G., Valentin, L., Rasmussen, C.K., Votino, A., Van Schoubroeck, D., Landolfo, C., Installé, A.J.F., Guerriero, S., Exacoustos, C., Gordts, S., Benacerraf, B., D'Hooghe, T., De Moor, B., Brölmann, H., Goldstein, S., Epstein, E., Bourne, T., Timmerman, D. **Terms, definitions and measurements to describe sonographic features of myometrium and uterine masses: a consensus opinion from the Morphological Uterus Sonographic Assessment (MUSA) group.** *Ultrasound Obstet. Gynecol.* 2015; 46: 284–298
- Yovich, J.L. **Management of Menorrhagia, Current Concepts.** Part I. *Br. J. Sexual Med.* 1979; 6: 37–40
- Yovich, J.L., Matson, P.L., Yovich, J.M. **The optimisation of laparoscopic oocyte recovery.** *Int. J. Fertil.* 1989; 34: 390–400
- Yovich, J.L., Lingam, S., Rowlands, P., Srinivasan, S. **Laparoscopic Myomectomy – Beware Adenomyosis.** *J. Fertil. In vitro IVF Worldw. Reprod. Med. Genet. Stem Cell Biol.* 2019; 6: 1. doi:10.4172/2375–4508.1000212

Received 22 January 2019; accepted 9 April 2019.